Università degli Studi di Torino – Dental School Lingotto
Insegnamento di Conservativa
Titolari: Prof. E. Berutti, Dr. N. Scotti, Dr. D. Pasqualini

I PERNI IN FIBRA

Nicola Scotti
nicola.scotti@unito.it

TECNICHE DI RICOSTRUZIONE

PROTESICHE O INDIRETTE

RESTAURATIVE O DIRETTE

TECNICHE DI RICOSTRUZIONE

Perni metallici a ritenzione intrinseca

Perni metallici con ritenzione passiva

Perni passivi non metallici



TECNICHE DI RICOSTRUZIONE

Perni metallici a ritenzione intrinseca

Perni metallici con ritenzione passiva

Perni passivi non metallici

TECNICHE DI RICOSTRUZIONE

Perni metallici a ritenzione intrinseca

Perni metallici con ritenzione passiva

Perni passivi non metallici

FIBRE IMPIEGATE IN ODONTOIATRIA

Fibre di Kevlar
Fibre di Carbonio

Fibre di Quarzo
Fibre di Vetro

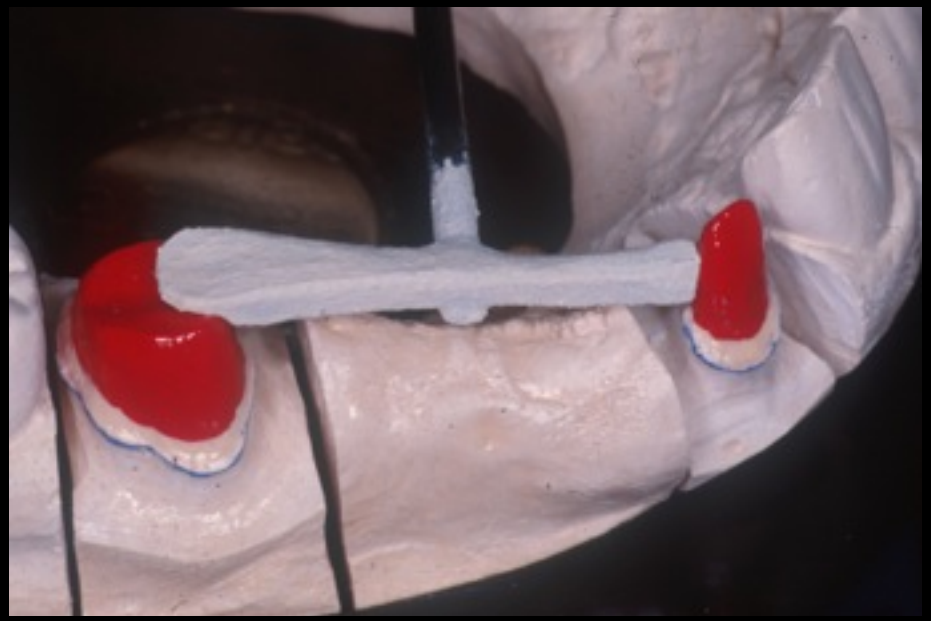

Lovell MJ:
The bond between CFRC and restorative materials
MS Thesis , University of London, 1983

Propone l'utilizzo di fibre di carbonio immerse in una matrice di natura organica

Malquarti G, Berruet RG,Bois D:
Prosthetic use of carbon fiber-reinforced epoxy resin for esthetic crowns and fixed partial dentures.
J Prosthet Dent 1990;63:251-257



Duret B, Reynaud M, Duret F.
Un nouveau concept de reconstituction corono-radiculaire: le Composipost
Le Chir Dent de France 1990;540:131-41

Duret B, Reynaud M, Duret F.
Un nouveau concept de reconstituction corono-radiculaire: le Composipost
Le Chir Dent de France 1990;542:69-77

Perno in resina epossidica rinforzato con fibre di Carbonio



modulo di elasticità simile alla dentina

caratteristica di anisotropia

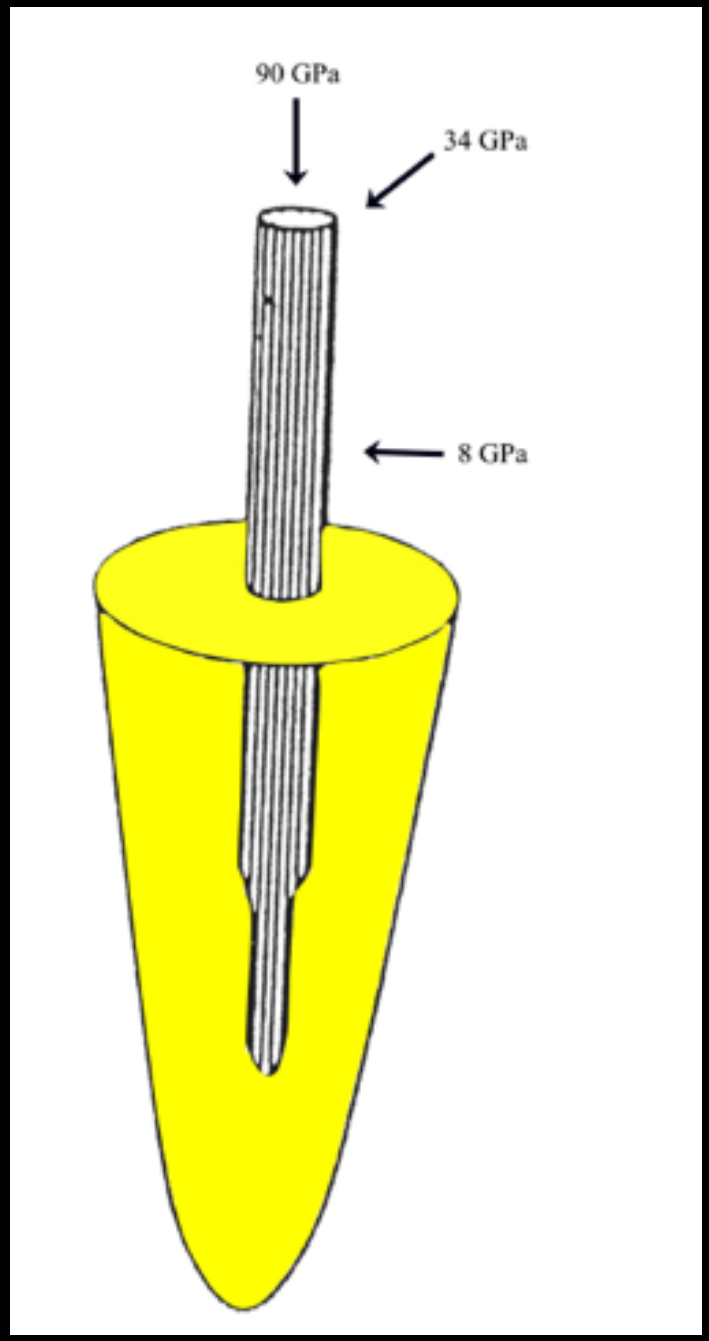

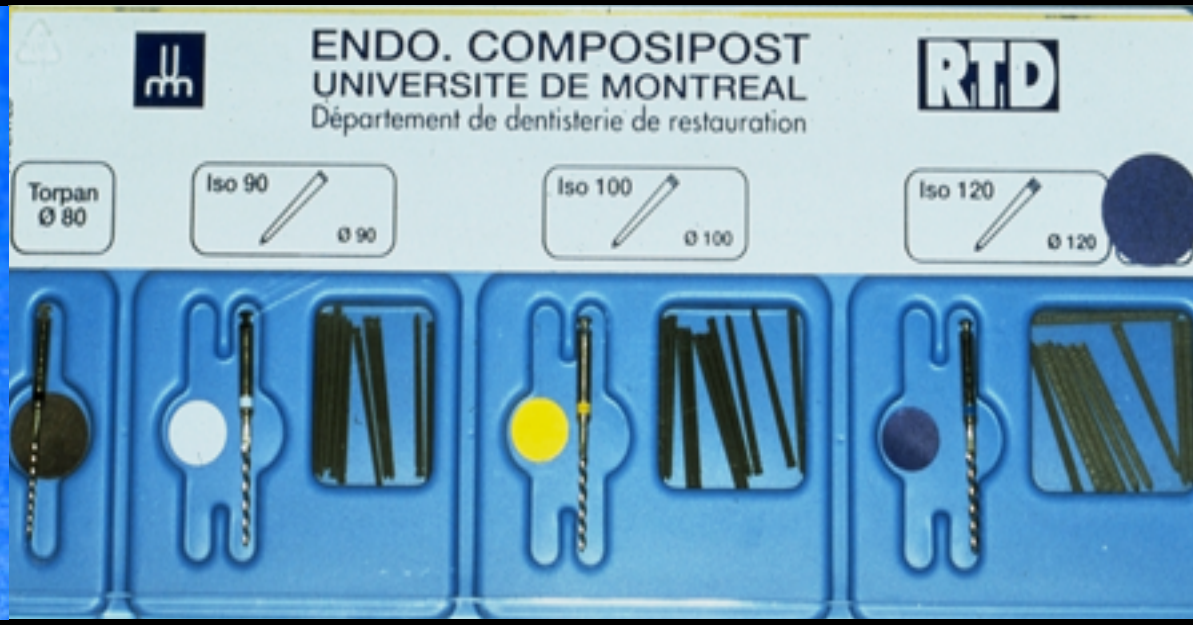

RADIOPACITA'



TIPI DI PERNI

DISTRIBUTORE	COSTRUTTORE	FIBRE CARBONIO	FIBRE VETRO
BONADENT	BONADENT GMBH	BONAFIT CARBON	BONAFIT GLASS FIBER
CABON-DENIT	RTD	ENDO-COMPOSIPOST COMPOSIPOST	LIGHT-POST DT LIGHT-POST
COLTENE	WHALEDENT		PARA POST FIBER WHITE
D.A.M.	BIOLOREN	NAUTILUS	NAUTILUS WHITE (SILICA)
DENTALICA	CARBOTECH		PRECISION ANATOMICAL POST
DENTATUS			LUSCENT ANCHORS
E. HAHNENKRATT	E. HAHNENKRATT	CYTES & EXATEC	CYTES & EXATEC
EUROPRISES	HOLLAND	FIBER POST	
GEBR BRASSELER	BRASSELER GMBH		ER DENTIN POST, FIBER GLASS
GHIMAS	BIOLOREN	CONIC 6% BLACK	CONIC 6% WHITE
HAGEN & WERKEN	HAGEN &WERKEN	MIRAFIT	MIRAFIT
HARALD NORDIN	HARALD NORDIN		GLASSIX
ISASAN	CARBOTECH	TECH 2000	FOTO TECH (ZIRCONIUM) TECH 21 XOP (SILICA)
IVOCLAR VIVADENT	IVOCLAR VIVADENT		FRC POSTEC
JENERIC PENTRON	J.P.		FIBREKOR POST
KRUGG	A.U.M.	EASY POST	EASY G POST
KOMET	KOMET		DENTIN POST
MAILLEFER DENTSPLY	MAILLEFER DENTSPLY		EASY POST
METALOR TECHNOLOGIES	METALOR TECHNOLOGIES SA		STYLE PO
R.O.E.N.	BIOLOREN	FIBER LINK ENDO CARBON PIVOT C POST BLACK MILLENIUM	CLEAR LINK ENDO GLASS PIVOT C POST WHITE MILLENIUM
SVENSKA DETORAMA	SVENSKA DETORAMA SA	DENTORAMA CARBON STABITECH	DENTORAMA GLASS GLASS FIBER PIVOT
SWEDEN & MARTINA	HARALD NORDIN	CARBONITE	GLASSIX
TECNO DENTA	CARBOTECH	SURGI POST	SURGI POST T (SILICA)


?
E.B.D.
?

RICERCA SCIENTIFICA

STUDI IN VITRO





STUDI IN VIVO

RICERCA SCIENTIFICA

RICERCA SCIENTIFICA

					INSUCCESSI			
					FRATTURA			
AUTORI	DATA	STUDI	TEMPO	CASI	radice	perno	distacco	fallimenti
Armand	1994	Retr.	4a	150	-	-	1	-
Decloquement	1994	Retr.	4a	400	-	-	12	-
Dallari	1994	Retr.	3.5a	160	-	-	-	-
Glazer	1995	Retr.	3.75a	59	-	1	1	7
Bolla et al	1995	Retr.	4a	137	-	1	4	-
Dallari	1997	Retr.	6a	350	-	-	1	-
Fredriksson	1998	Retr.	3a	236	-	-	-	5
Ferrari et al	2000	Retr.	1-6a	1304	-	-	25	16
Ferrari et al	2000	Retr.	4a	100	-	-	-	5
Malferrari et al	2002	Prosp.	2.5a	258	-	1	2	-
Ferrari et al	2002	Retr.	1a	40	-	-	-	2
Malferrari et al	2003	Prosp.	2.5a	180	-	1	2	-

TIPI DI INSUCCESSO

FRATTURA ADESIVA

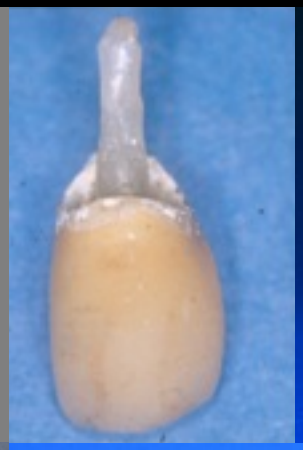

FRATTURA COESIVA

FRATTURA ADESIVA-COESIVA


10kV X75
100µm

Malferrari S, Monaco C, Scotti R.
Clinical Evaluation of Teeth Restored with Quarts Fiber-Reinforced Epoxy Resin Posts.
Int J Prosthodont 2003;1(16):39-44

Conclusions

1. Within a 30-month period, 205 Æstheti-Plus quartz-fiber posts were used to restore 180 teeth with clinical success. The three failures recorded represented 1.7% of treated teeth.
2. All three failures occurred during the temporary phases. The cohesive fracture and two adhesive fractures involved only the post-and-core restoration. No root or post fractures occurred.
3. In the case of failure, it was possible to replace the restoration without losing the element.

ADESIONE INTRACANALARE

Intertubular Resin Infiltration

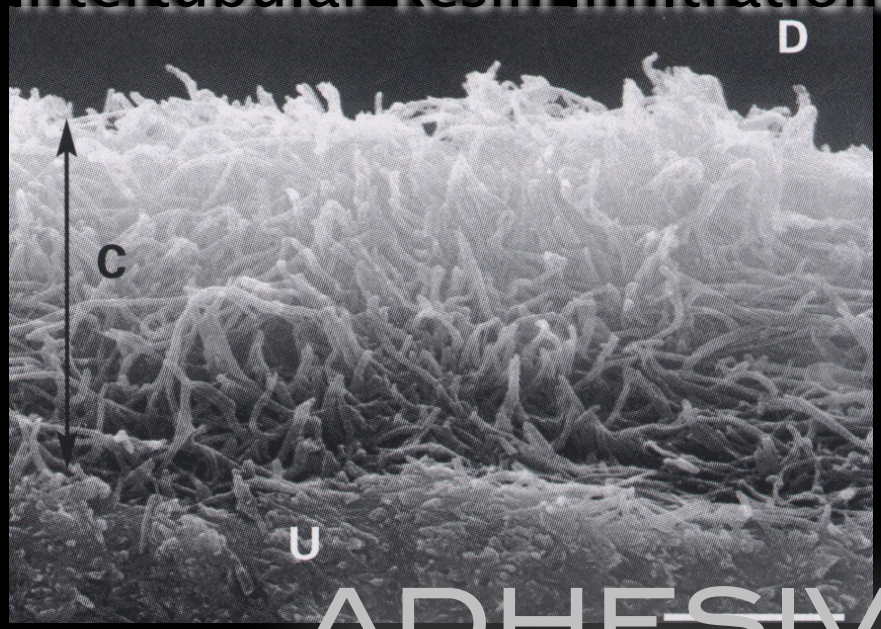

Intratubular Resin Infiltration



ADHESIVE DENTISTRY

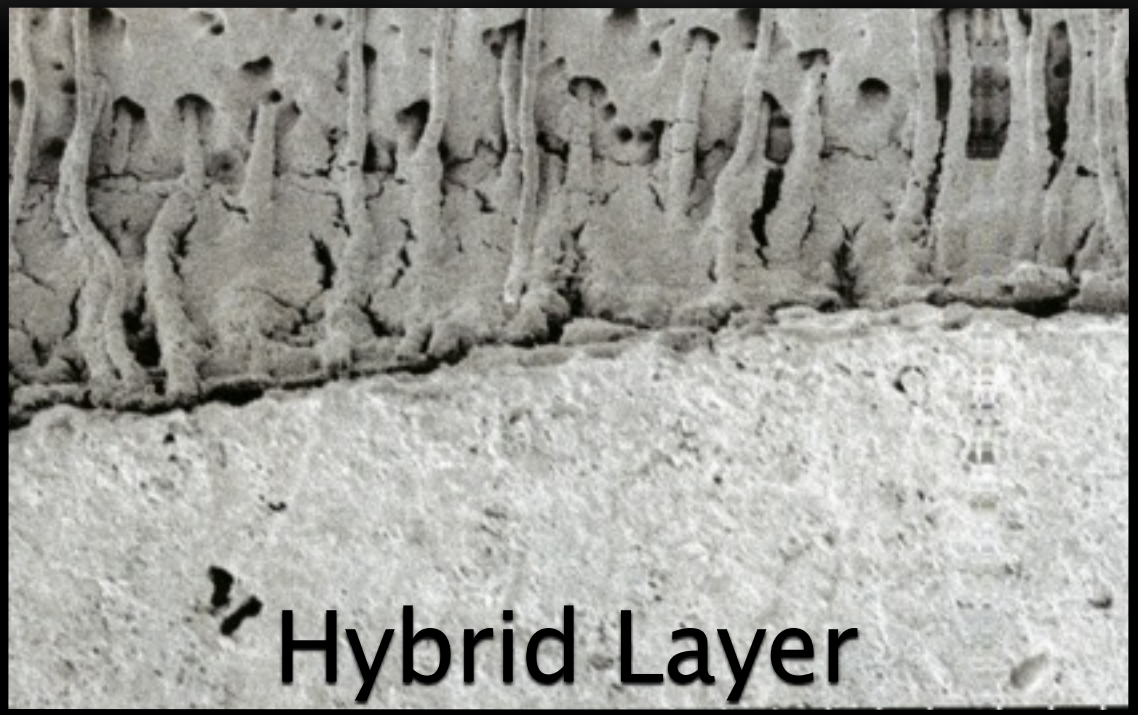

ADESIONE INTRACANALARE







"At middle and coronal levels areas of clean dentin, alternating with areas covered by thin smear layer, smaller debris, gutta-percha remnants, and orifices of tubules partially or totally occluded by plugs were frequently observed"

"Higher amounts of rough debris, large sealer/gutta-percha remnants, thick smear layer, and no visibility of tubule orifices were recorded in all the groups at apical level of post space."

Serafino C, Gallina G, Cumbo E, Ferrari M. Surface debris of canal walls after post space preparation in endodontically treated teeth: a scanning electron microscopic study. *Oral Surg Oral Med Oral Pathol Oral Radiol Endod.* 2004 Mar;97(3):381-7

ADESIONE INTRACANALARE

"…ideally resin tags should bond to the tubule walls…under such conditions, whenever the tag is stressed, it is more likely to fail cohesively at the top of the tubule orifice than adhesively at the tubule wall."







Pashley DH, Sano H, Ciucchi B, Carvalho RM, Russell CM. Bond strength versus dentin structures: a modeling approach. *Arch Oral Biol* 1995;40:1109-1118.

SUBSTRATO DENTINALE

YOUNG DENTINE
EDTA 60 SEC

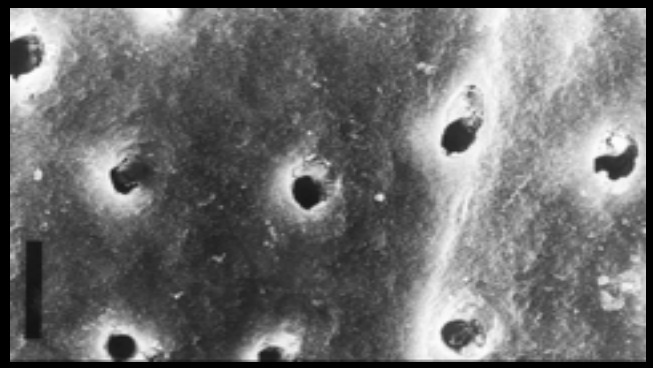

SCLEROTIC DENTINE
EDTA 60 SEC

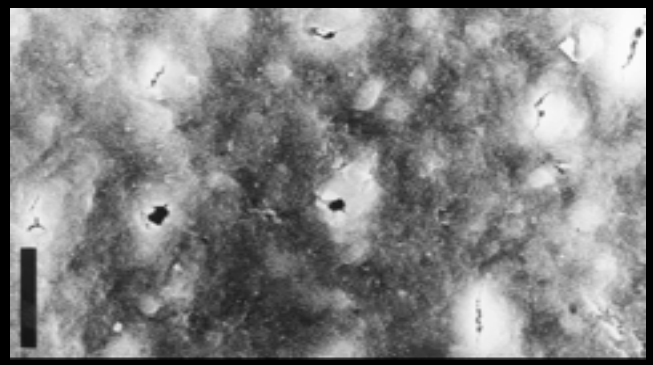

SCLEROTIC DENTINE
H_3PO_4 30 SEC

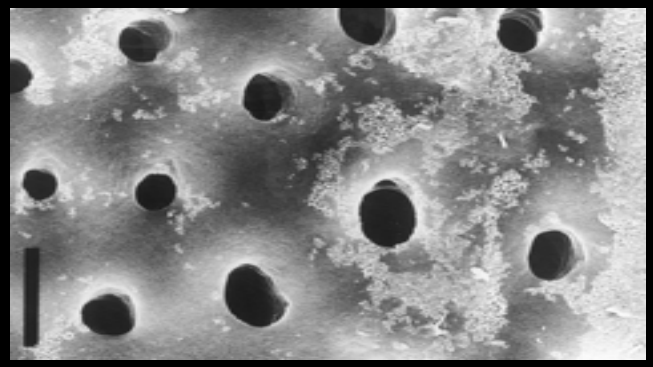

Kusunoki M, Itoh K, Hisamitsu H, Wakumoto S. The efficacy of dentine adhesive to sclerotic dentine. *J Dent* 2002; 30: 91–97

SUBSTRATO DENTINALE

"...we speculate that the degradation of the demineralized dentin matrix was due to enzymes that were from the underlying mineralized matrix slowly released during the 250-day incubation."

"...the partial to complete disappearance of the DCM in specimens that were retrieved from the artificial saliva after 250 days provided morphologic evidence of the effectiveness of the collagenolytic activity assayed in powdered dentin."

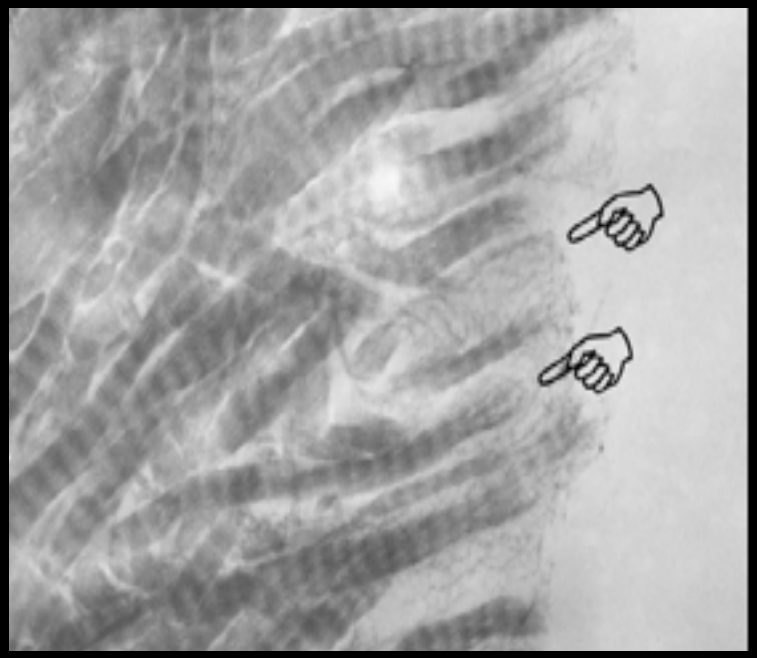

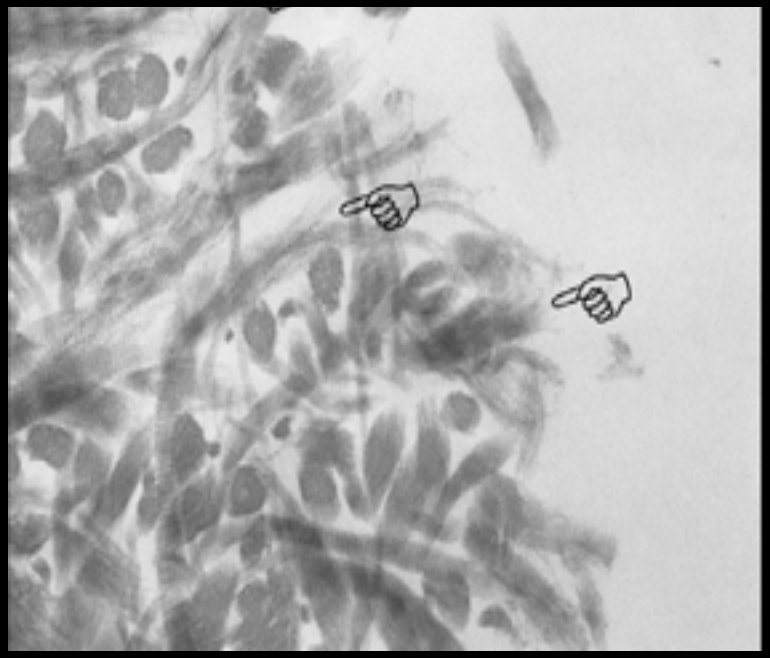

Pashley DH, Tay FR, Yiu C, Hashimoto M, Breschi L, Carvalho RM, Ito S. Collagen degradation by host-derived enzymes during aging. *J Dent Res* 2004;83:216-221

SUBSTRATO DENTINALE

2 anni	8-10 %
10 anni	20 %

Vital Element

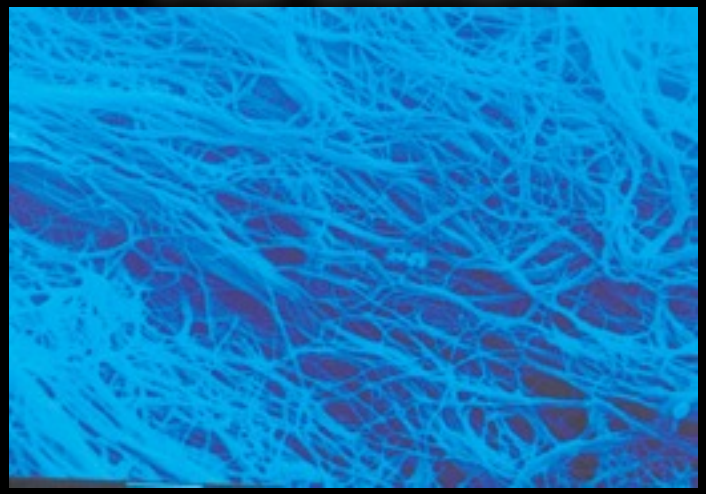

5 Years Before

10 Years Before

Mason PN. Bonding to root canal dentin. Transactions of Academy of Dental Materials Meeting, Siena 2001, 65-69

SUBSTRATO DENTINALE

GRUPPO CONTROLLO

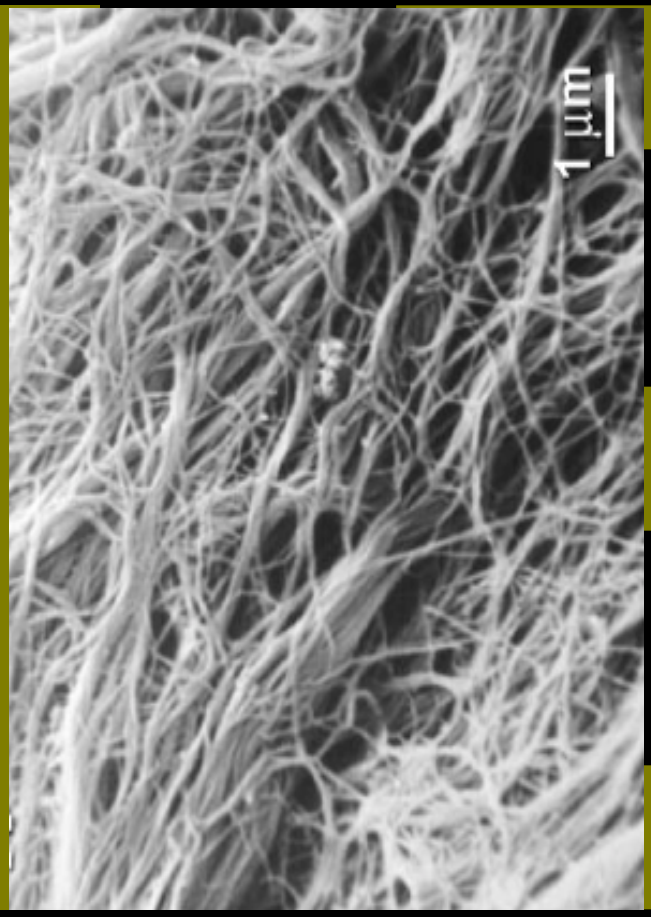

3-5 ANNI

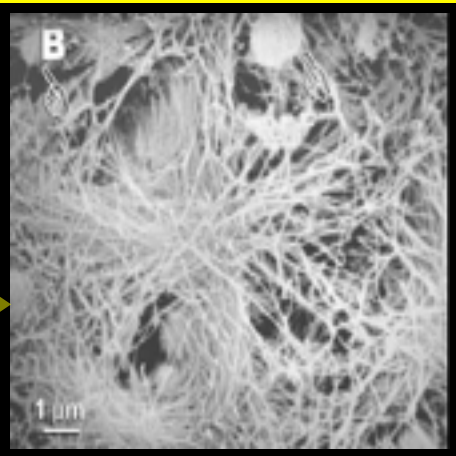

6-9 ANNI

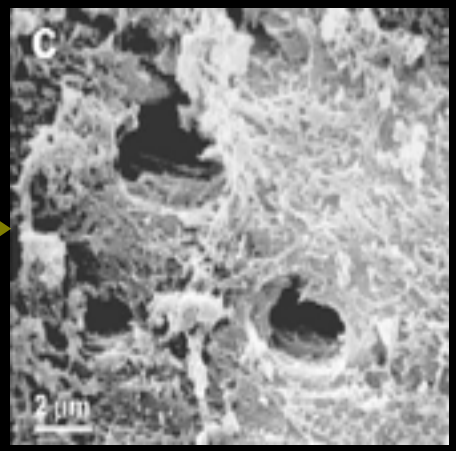

10-12 ANNI

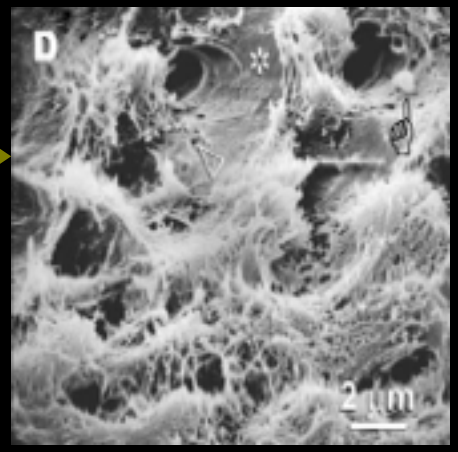

Ferrari M, Mason PN, Goracci C, Pashley DH, Tay FR. Collagen degradation in endodontically treated teeth after function. *J Dent Res* 2004;83(5):414-419

SUBSTRATO DENTINALE

Gruppo	N	Media	Dev Std.	SEM	I.C. 95%
1	27	19.01	2.25	0.43	3.61-6
2	28	14.20	2.15	0.40	
t= 8.104 ; 53 gl ; p<0.001					




Ellena F, Tamagnone L, Ullio L, Beccio R, Stuffer F, Berutti E. Adesione dei perni alla dentina radicolare nei differenti trattamenti endodontici. Sessione Poster, XXVII Congresso Nazionale SIE, Verona 2006

SUBSTRATO DENTINALE

...in conclusione

La degenerazione delle fibre collagene riduce il substrato disponibile all'adesione intracanalare

Un'attenta rimozione dei detriti dentinali è quanto mai necessaria nella ricostruzione di denti ritrattati endodonticamente

Studi clinici sono necessari per verificare protocolli di adesione efficaci per la ricostruzione del dente trattato endodonticamente